

What is an automated 3D ultrasound?

3D ultrasound is one of the most promising new technologies. Instead of flat, 2D images, this powerful ultrasound technology gives your doctor a much more realistic view of the whole breast and its physical structures; providing multiple views—side to side, back to front and more.

Does 3D ultrasound replace mammography?

Absolutely not. Mammography is considered the gold standard in breast screening, but it misses or overlooks roughly 10 percent of the cancers in women with dense breast tissue. A single screening ultrasound following a standard mammogram increases detection of breast cancers that are small.



In cancer cases, 1/4 are discovered by ultrasound but missed by mammography.

For more information contact the
Imaging Department at
Columbus Regional Healthcare System
910-642-1775

Columbus  Regional
HEALTHCARE SYSTEM

500 Jefferson St.
Whiteville, NC 28472
Phone: (910) 641-8282
Fax: (910) 642-9450
www.crhealthcare.org

Columbus  Regional
HEALTHCARE SYSTEM



3D ULTRASOUND
FOR
DENSE BREAST TISSUE

Columbus Regional's Automated Breast Ultrasound (ABUS), also known as 3D ultrasound, is a secondary breast cancer diagnostic tool for women with dense breast tissue.



How do I know if I have dense tissue?

Having dense tissue does not necessarily mean that your breasts are lumpy, thick, heavy or cystic. The radiologist sees the density when reading your mammogram. Breast tissue density is classified into four categories. Your density category will be on your mammogram report that is sent to your doctor. CRHS will also notify you of your density category and advise you if another test, screening breast ultrasound, should be considered.

If I have dense tissue should I still have a mammogram?

The mammogram is still important and valuable because even when there is dense tissue it will show some signs of early breast cancer, such as calcifications, better than other tests.

So what can be done if I have dense tissue?

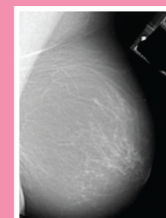
For women with heterogeneously or extremely dense breast tissue, a breast ultrasound in addition to the mammogram is recommended. At CRHS, we offer an automated 3D ultrasound, which is the latest technology in breast imaging. This exam can be offered the same day as the routine screening. Its quick and painless; no compression and the exam only takes 52 seconds per breast.

What if my tissue is not dense?

If your breast tissue is not dense, and has almost entirely fatty or scattered fibroglandular tissue, the mammogram is all that is necessary to yearly screening.

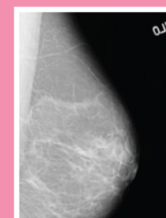
There are four categories that are used to describe the amount of dense tissue seen on the mammogram which is reported by the radiologist who reads your mammogram.

Breast Density Using a 4-Level Scale



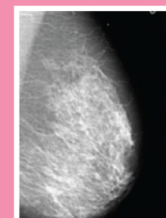
Almost entirely Fat Density

Fatty tissue looks dark gray or black on the mammogram.



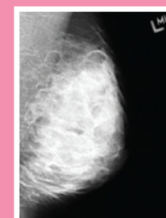
Scattered Fibroglandular Density

There is some fibroglandular or white tissue scattered on the background of fatty or dark gray tissue. Most small masses are still easy to detect.



Heterogeneously Dense

There is more fibroglandular dense in some areas than fatty or dark tissue. There is enough dense tissue to obscure small masses that may be hidden.



Extremely Dense

Most of the breast tissue contains dense or white tissue.

If you or someone you know is dealing with a breast health issue, now is the time to start asking questions. The more you learn about today's latest treatments, technologies and breast pathologies, the better equipped you will be to make smart decisions concerning tests, treatment plans and recovery. This is particularly true if you have a history of breast disease or have dense breast tissue.

What does dense tissue mean and why is it important?

Dense tissue may hide or obscure some signs of cancer. Breast cancer may look like a white spot on the mammogram and dense tissue also looks like white on the mammogram. So, small white spots are not as easy to detect in areas of the mammogram that show a background of dense or white tissue.

About one half of women have more fatty tissue in their breasts that appears dark gray on the mammogram. For these women the mammogram is more reliable at showing these white spots which could be cancer. The other half of women have dense tissue which makes the mammogram less reliable at detecting small or early breast cancer.